

# Pembrolizumab Associated Hypothyroidism: Case Report and Review of Literature

Niranjan Tachamo<sup>1</sup>, Saroj Lohani<sup>1</sup>, Salik Nazir<sup>1\*</sup>, Rishikesh Joshi<sup>2</sup> and Mrunalini Deshmukh<sup>1</sup>

<sup>1</sup>Internal Medicine Department, Reading Health System, Sixth Avenue and Spruce Street, Wyomissing, PA 19611, USA

<sup>2</sup>Tribhuvan University, Kathmandu, Nepal

Received Date: June 01, 2017, Accepted Date: June 15, 2017, Published Date: June 27, 2017.

\*Corresponding author: Salik Nazir, Internal Medicine Department, Reading Health System, Sixth Avenue and Spruce Street, Wyomissing, PA 19611, USA, E-mail: saliknazir133@gmail.com.

## Abstract

**Context:** Pembrolizumab is a Programmed Death 1 (PD-1) inhibitor used to treat advanced malignant melanoma and metastatic non-small cell lung cancer. It causes various endocrinological side effects including immune mediated thyroiditis. Thyroiditis caused by Pembrolizumab can mimic other immune mediated thyroiditis like Hashimoto thyroiditis and Grave's disease.

**Case Report:** A 61 year old male who was receiving treatment with pembrolizumab for malignant melanoma was evaluated for abnormal Thyroid Function Tests (TFTs). His TFTs were normal before chemotherapy, however, TFTs done one month after fourth cycle of chemotherapy revealed suppressed TSH. Follow up of TFTs two months after fourth cycle of chemotherapy and there after revealed persistent elevated TSH concerning for hypothyroidism. Other potential causes of abnormal thyroid function were ruled out by history and negative antibody tests. He was started on levothyroxine for hypothyroidism.

**Conclusion:** Pembrolizumab, similar to other PD-1 inhibitors causes various endocrinological side effects via immune mediated mechanism. Thyroiditis is more common with pembrolizumab than ipulimumab. Diagnosis requires high index of suspicious and frequent monitoring of TFT while on treatment is based on symptoms and thyroid function tests. Hospitalization and treatment with steroids is indicated in severe cases.

**Keywords:** Autoimmune thyroiditis; Pembrolizumab; Thyroid function test (TFT)

clinic because of abnormal thyroid function test. He was receiving treatment with pembrolizumab for metastatic melanoma. He had already completed four cycles of chemotherapy. He denied any signs or symptoms of hyperthyroidism. He did not have history of recent upper respiratory tract infection, use of iodine tablets, recent surgery, recent imaging using iodine contrast dye, radiation to neck, or use of any herbal or food supplements. He did not have family history of thyroid problems.

Regarding his vital signs, his temperature was 98° F, pulse was 74/minute, respiratory rate was 14/minute and blood pressure was 149/83 mmHg. Physical exam didn't reveal any thyroid mass or tenderness. Rest of the physical exam was within normal limits.

## Investigations

Review of his labs done prior to clinic visit showed normal complete blood count, basic metabolic profile and liver function tests. Baseline thyroid function tests (TFTs) before the chemotherapy showed Thyroid Stimulating Hormone (TSH) of 1.295 uIU/ml (normal 0.3–5 uIU/ml), free T4 of 0.79 (normal 0.58–1.64 ng/dl) and free T3 of 3.37 pg/ml (normal 2.2–4.1 pg/ml). His TFTs done after one month of fourth-cycle of chemotherapy revealed TSH of 0.022 uIU/ml, free T4 of 4.23 ng/dl and free T3 of 10.22 pg/ml. Because of the abnormal TFT he was referred to our thyroid clinic. Thyroid uptake scan with imaging showed diffusely decreased uptake with no cold or hot nodule suggestive of thyroiditis.

TFTs done after two month of fourth-cycle of chemotherapy revealed TSH of 10.7, fT4 of 0.42 and fT3 of 2.75. Thyrotropin receptor antibody (TRab) of the stimulating type (Thyroid Stimulating Immunoglobulin-TSI), Anti Thyroid Peroxidase (Anti TPO) antibody and Anti thyroglobulin (Anti TG) antibody were negative. The result of his thyroid function tests is summarized in the following graph (Figure 1).

## Differential Diagnosis

The thyroid function tests of our patient were normal prior to treatment. His TFTs done after one month of fourth-cycle of chemotherapy showed suppressed TSH. That in the setting of decreased thyroid uptake was consistent with thyroiditis. Analysis of TFTs two months after the fourth-cycle of chemotherapy and thereafter revealed hypothyroidism.

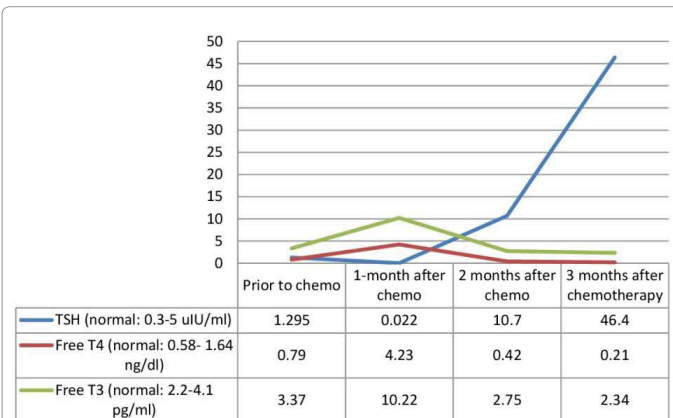
Graves' disease is the leading cause of hyperthyroidism that presents with thyrotoxic signs (such as tremors, hyperactive deep tendon reflexes, tremor & etc.) and symptoms (such as weight loss, palpitations, anxiety, loss of sleep etc.), together with evidence of ophthalmopathy or dermopathy. Patients presenting with thyrotoxic signs and symptoms, and elevated TFTs usually do not improve without medications in few weeks. Our patient did not have clinical stigmata of Graves' disease or anti TSH

## Introduction

Pembrolizumab is a Programmed Death 1 (PD-1) inhibitor used to treat advanced malignant melanoma and metastatic non-small cell lung cancer. It was recently approved by United States Food and Drug Administration (FDA) for treatment of unresectable and advanced stage malignant melanoma [1]. The most common side effects of Pembrolizumab noted in various trials are fatigue, pruritus and nausea [2,3]. Pembrolizumab like other PD-1 inhibitors also causes various endocrinological side effects such as hypophysitis, thyroiditis and adrenalitis via immune mediated mechanism. The incidence of thyroiditis is more common with pembrolizumab than ipulimumab [4]. We report a case of a 61 year old male who underwent chemotherapy with pembrolizumab for metastatic malignant melanoma and was referred to endocrinology for abnormal thyroid function test. Further work up revealed drug induced hypothyroidism. In this report we aim to highlight the importance of early recognition of hypothyroidism secondary to Pembrolizumab and present a brief review of literature.

## Case Presentation

A 61 year old male with history significant for malignant melanoma stage III A of right lower extremity metastatic to inguinal, axillary and pelvic nodes was referred to the thyroid



**Figure 1:** Chart showing trend of thyroid function test (TFT) in our patient.

receptor stimulating antibodies. Lack of tenderness over thyroid area, and no recent viral infection ruled out subacute thyroiditis. Hashimoto thyroiditis was ruled out by negative anti TPO antibody and negative family history of hashimoto thyroiditis. After ruling out all the above causes, we were left with drug-induced thyroiditis leading to hypothyroidism, patient wasn't taking other drugs known for causing hypothyroidism such as Amiodarone, Interferon alfa, Lithium etc. Hence more plausible explanation could be immune mediated thyroiditis leading to hypothyroidism secondary to Pembrolizumab. The patient was contacted one week after the clinic visit. He did not have any symptoms suggestive of hypothyroidism or hyperthyroidism. He denied any neck pain or swelling. He was started on oral levothyroxine 50 mcg. However, he complained of palpitations after the first dose and his dose was reduced to 25 mcg daily.

## Outcome and Follow-Up

Thyroid function tests done three months after fourth cycle of chemotherapy revealed TSH of 46.44, free T4 of 0.21 and free T3 of 2.34. He had complaints of feeling tired and sleepy, other than that he did not have any symptoms of hypothyroidism. Physical examination revealed normal vital signs and normal physical exam findings. Levothyroxine was increased to 50 mcg daily with repeat TFT in six weeks.

## Discussion

Pembrolizumab is an anti-Programmed Death 1 (PD-1) monoclonal antibody. The PD-1 receptor is a negative regulator of T-cell effector mechanisms that limits immune responses against cancer [5]. Pembrolizumab was approved by United States Federal Drug Administration (FDA) in September 2014 for treatment of unresectable or advanced Stage III and IV malignant melanoma [1]. After the Phase II trial (conducted from 2012 to 2013), the authors decided that the data was sufficient to support accelerated approval of pembrolizumab by FDA for treatment of advanced and unresectable malignant melanoma [6]. Hence pembrolizumab received priority drug review and accelerated approval by FDA for treatment of advanced and unresectable malignant melanoma [1]. It has demonstrated remarkable activity in patients with advanced melanoma regardless of whether they were previously treated with ipilimumab or not [5]. Phase one trial of pembrolizumab in ipilimumab refractory malignant melanoma was published in 2014 [2]. It included 173 patients. The most common side effects of pembrolizumab noted in the trial were fatigue, pruritus and rash [2]. None of the patients enrolled in phase one trial developed

thyroid related side effects either in 2 mg/kg pembrolizumab group or 10 mg/kg pembrolizumab group. Phase II trial of pembrolizumab in ipilimumab refractory or in BRAF V600 treatment with BRAF or MEK inhibitor or both involving 540 patients was eventually published in 2015 [3]. The most common adverse effects noted in this trial were fatigue, pruritus and nausea. Hypothyroidism was noted in nine patients (5%) in the group which received 2 mg/kg of pembrolizumab and 13 patients (7%) who received 10 mg/kg of pembrolizumab [3]. No additional details about the hypothyroid side effect could be found. The patient in our case was receiving 2 mg/kg pembrolizumab every three weeks. Immune mediated dysfunction of endocrine organs (thyroid, pituitary, adrenal) is a common side of PD-1 inhibitors [4]. Hypophysitis is common with ipilimumab whereas thyroiditis is more common with pembrolizumab/nivolumab [4].

Pembrolizumab is also used to treat advanced non-small cell lung cancer and mesothelioma. In phase III trial of pembrolizumab in advanced non-small cell lung cancer, hypothyroidism was reported in 8% of cases and hyperthyroidism was reported in 2-4 % of cases [7].

Drug induced thyroiditis secondary to Pembrolizumab can manifest in various ways. It can manifest as primary hypothyroidism due to destructive thyroiditis or by hyperthyroidism associated with Graves' disease. Occasionally as in our case it can manifest as transient hyperthyroidism followed by longstanding hypothyroidism. Most of the times the symptoms of thyroiditis are non-specific such as fatigue hence high degree of suspicion is required for timely diagnosis. Since the symptoms are similar, sometimes we might need to distinguish primary hypothyroidism from secondary hypothyroidism (usually in case of hypophysitis). This can be done by correct interpretation of TFTs (high TSH and low free T4 indicates primary hypothyroidism whereas low TSH and low free T4 is suggestive of hypophysitis). It has been advised to check baseline TSH prior to chemotherapy and routinely at each dose of PD1 inhibitors even in absence of symptoms [4].

No antibody has been discovered till now to diagnose immune-mediated thyroiditis secondary to pembrolizumab. Treatment depends upon the presence or absence of symptoms and the severity [7]. In asymptomatic patients, no treatment is indicated and only monitoring of TFTs is advised. Intervention is indicated for symptomatic cases. For mild symptoms, treatment is levothyroxine for hypothyroidism and beta blockers for hyperthyroidism. For severe symptoms, hospitalization and treatment with steroids can be considered. Regular monitoring of TFTs is indicated in all cases following treatment.

In 10-15 % of patients with chronic autoimmune thyroiditis such as hashimoto thyroiditis anti-TPO antibodies can be negative. Hence it is quite plausible that in our patient the hypothyroidism developed as a consequence of hashimoto thyroiditis. We believe that the temporal relationship with pembrolizumab therapy and the rapidity of TFT abnormality suggest drug induced thyroiditis from pembrolizumab

## Learning Points

- I. Pembrolizumab can cause immune-mediated thyroiditis.
- II. Mild cases of symptomatic thyroiditis can be treated symptomatically whereas severe cases require hospitalization and treatment with immunosuppressants.
- III. Patients undergoing treatment with pembrolizumab should be monitored for immune mediated side effects like thyroiditis, hypophysitis, adrenalitis.

## Conflict of Interest

The authors declare that there is no conflict of interest.

## References

1. Press Announcements - FDA approves Keytruda for advanced melanoma. Available from: <http://www.fda.gov/NewsEvents/Newsroom/PressAnnouncements/ucm412802.htm>.
2. Robert C, Ribas A, Wolchok JD, Hodi FS, Hamid O, Kefford R, et al. Anti-programmed-death-receptor-1 treatment with pembrolizumab in ipilimumab-refractory advanced melanoma: a randomised dose-comparison cohort of a phase 1 trial. *Lancet*. 2014;384(9948):1109-17. doi: 10.1016/S0140-6736(14)60958-2.
3. Hamid O, Robert C, Daud A, Hodi FS, Hwu WJ, Kefford R, et al. Safety and tumor responses with lambrolizumab (anti-PD-1) in melanoma. *N Engl J Med*. 2013;369(2):134-44. doi: 10.1056/NEJMoa1305133.
4. Sullivan RJ, Flaherty KT. Immunotherapy: Anti-PD-1 therapies-a new first-line option in advanced melanoma. *Nat Rev Clin Oncol*. 2015;12(11):625-6. doi: 10.1038/nrclinonc.2015.170.
5. Ribas A, Puzanov I, Dummer R, Schadendorf D, Hamid O, Robert C, et al. Pembrolizumab versus investigator-choice chemotherapy for ipilimumab-refractory melanoma (KEYNOTE-002): a randomised, controlled, phase 2 trial. *Lancet Oncol*. 2015;16(8):908-18. doi: 10.1016/S1470-2045(15)00083-2.
6. Torino F, Corsello SM, Salvatori R. Endocrinological side-effects of immune checkpoint inhibitors. *Curr Opin Oncol*. 2016;28(4):278-87. doi: 10.1097/CCO.0000000000000293.
7. Spain L, Diem S, Larkin J. Management of toxicities of immune checkpoint inhibitors. *Cancer Treat Rev*. 2016;44:51-60. doi: 10.1016/j.ctrv.2016.02.001.

**\*Corresponding author:** Salik Nazir, Internal Medicine Department, Reading Health System, Sixth Avenue and Spruce Street, Wyomissing, PA 19611, USA, E-mail: [saliknazir133@gmail.com](mailto:saliknazir133@gmail.com).

**Received Date:** June 01, 2017, **Accepted Date:** June 15, 2017, **Published Date:** June 27, 2017.

**Copyright:** © 2017 Tachamo N, et al. This is an open access article distributed under the Creative Commons Attribution License, which permits unrestricted use, distribution, and reproduction in any medium, provided the original work is properly cited.

**Citation:** Tachamo N, Lohani S, Nazir S, Joshi R, Deshmukh M (2017) Pembrolizumab Associated Hypothyroidism: Case Report and Review of Literature. *J Int Med Pat Care* 1(1): 101.