

A Rare Case of Peritoneal Carcinomatosis Leading to Bowel Obstruction Due to Metastatic Lung Cancer

Molly S. Jain^{1*}, Enkhmaa Luvsannyam², Abubaker R.Kallan², Nasihudeen Aziz³, Abbas Hasnie¹, Austin F. Tiesenga⁴, and Frederick M. Tiesenga⁵

¹Saint James School of Medicine, Cane Hall Road, Arnos Vale, St. Vincent & Grenadines

²Avalon University School of Medicine, 122 - 124 Santa Rosaweg, Curacao

³Windsor University School of Medicine, P.O.Box 1621 Brighton's Estate, Cayon St. Kitts, Cayon, St Kitts & Nevis

⁴Liberty University College of Osteopathic Medicine, 306 Liberty View Ln, Lynchburg, VA 24502, United States

⁵Chairman of Surgery & President of Medical Staff, Director of Minimally Invasive and Robotic Surgery; West Suburban Hospital, 3 Erie St, Oak Park, IL 60302, United States

Received Date: August 19, 2020, **Accepted Date:** September 11, 2020, **Published Date:** September 18, 2020.

***Corresponding author:** Molly S. Jain, MS3, Saint James School of Medicine, 3321 Conservation Drive, Windsor ON N8W 5P2, CANADA, Tel:810-986-3063; E-mail: mjain@mail.sjms.org

Abstract

In this report, we present a rare case of a 52-year-old male patient with a history of smoking who presented to the emergency room with acute abdominal pain and vomiting. The patient was diagnosed with non-small cell lung cancer (NSCLC) one month prior. Abdominal computerized tomography (CT) scan showed peritoneal carcinomatosis with severe small bowel obstruction (SBO). During an emergent exploratory laparotomy, biopsy samples were taken and a proximal diverting loop ileostomy was performed as a palliative care measure. This case highlights the need to be cognizant about the metastasis of primary lung cancer to the peritoneum leading to small bowel obstruction, and how to achieve palliative care.

Keywords: Bowel obstruction, Exploratory laparotomy; Loop ileostomy; Lung cancer; Peritoneal carcinomatosis

Abbreviations

NSCLC: Non-Small Cell Lung Cancer; CT: Computerized Tomography; SBO: Small Bowel Obstruction; GI: Gastrointestinal; MRI: Magnetic Resonance Imaging; JP: Jackson-Pratt; IHC: Immunohistochemical; CK7: Cytokeratin 7; TTF-1: Thyroid transcription factor-1; HIPEC: Hyperthermic Intraperitoneal Chemotherapy; ORR: Objective Response Rate; PFS: Progression-Free Survival.

Introduction

Lung cancer accounts for more deaths than any other type of cancer in the United States. It is estimated that 40-50% of patients present with distal metastasis at the time of lung cancer diagnosis leaving behind <5% of survival rate [1]. This makes lung cancer highly associated with poor patient prognosis [1]. Traditionally, the advancement of this cancer presents with metastasis to the brain, liver, bone, kidney and the adrenal glands [2]. The metastasis of the lung cancer to the gastrointestinal (GI) tract is of low occurrence, accounting for only 11.9% of primary lung cancer cases [3]. Rarely in 2% cases, the progression of cancer can lead to hematogenous spread towards the bowel involving the GI tract [4].

Some fatal complications of peritoneal metastasis include bowel obstruction, perforation, GI bleeding, and even intussusception [4]. Bowel obstruction is a common

emergent surgical presentation with a multifactorial cause most commonly involving intra-abdominal adhesions in approximately 70% of the cases. It usually presents with acute abdominal pain, changes in bowel movements including constipation, vomiting, loss of appetite and swelling of the abdomen. A perforation is over two times more likely to occur compared to an obstruction, 42% and 20.4%, respectively [1].

Small bowel obstruction normally could be treated with supportive care and surgical interventions however it gets quite challenging to manage when the patient has a low life expectancy in the case of advanced carcinoma. The dilemma remains to consider the advantages and disadvantages, which can help the patient receive the most beneficial care to improve the quality of life. Hence, surgical palliative options remain the basis for helping with small bowel obstruction as a result of metastasis from advanced lung carcinoma. The report discusses an unusual metastasis of lung cancer to the small intestine.

Case Report

We present a case of a 52-year-old African American male with intestinal metastasis from advanced lung cancer. Two months prior, the patient presented to the emergency department due to recurrent syncope. At that time, brain magnetic resonance imaging (MRI) was done and revealed right occipital intracranial metastasis with adjacent vasogenic edema (Figure 1). The patient also had

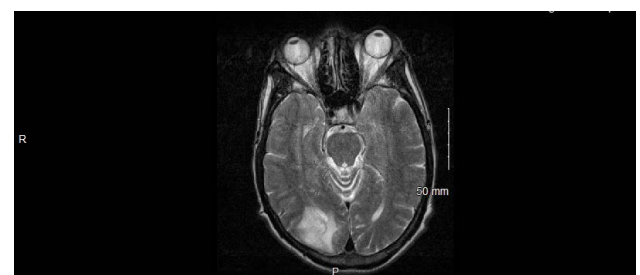


Figure 1: Brain MRI showed right occipital intracranial metastasis with adjacent vasogenic edema.

a chest X-ray which showed a superior mediastinal mass with left pulmonary opacities (Figure 2). A large lobulated mediastinal mass and spiculated cavitary nodule within the left upper lobe were identified on chest CT scan (Figure 3). US-guided left supraclavicular mass biopsy confirmed the diagnosis of adenocarcinoma by showing that the tumor cells are immunoreactive with CK 7, TTF-1 and Napsin A.

Patient’s past social history is significant for smoking a pack of cigarettes a day for 12 years, smoking marijuana, drinking 6-pack of alcohol every-other-day and working as a mechanic for 18 years. He has no other significant past medical or family history.

One month after the diagnosis of lung adenocarcinoma, the patient presented to the emergency department with a chief complaint of episodic abdominal pain for more than three weeks which had worsened for the last three days symptomatic with vomiting. The abdominal CT scan was consistent with peritoneal carcinomatosis leading to high-grade small bowel obstruction (Figure 4). On emergent exploratory laparotomy, we identified diffuse carcinomatosis with seeding of the entire small bowel (Figure 5). Peritoneal mass biopsy was taken and sent to the Department of Pathology for histopathological examination. Further exploration of the abdominal cavity revealed large masses within the small bowel and a large pelvic mass, making it impossible to free the bowel obstruction. At this time, a decision was made to perform a proximal diverting loop ileostomy in the right lower quadrant and a Jackson-Pratt (JP) drain was put in the left abdomen before the wound was closed (Figure 5). Patient’s postoperative course was uneventful.

Peritoneal biopsy analysis revealed nodules of large malignant cells in adipose tissue, consistent with peritoneal

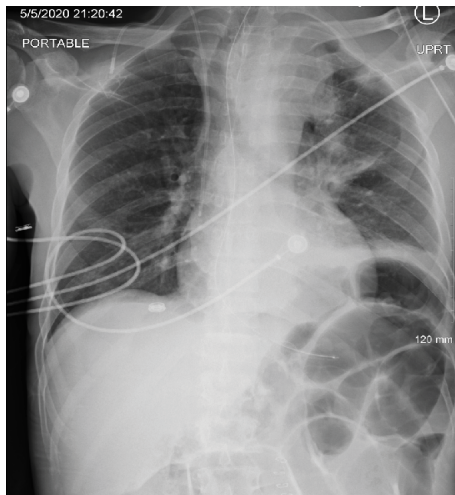


Figure 2: Chest X-ray showed superior mediastinal mass and left pulmonary opacities.

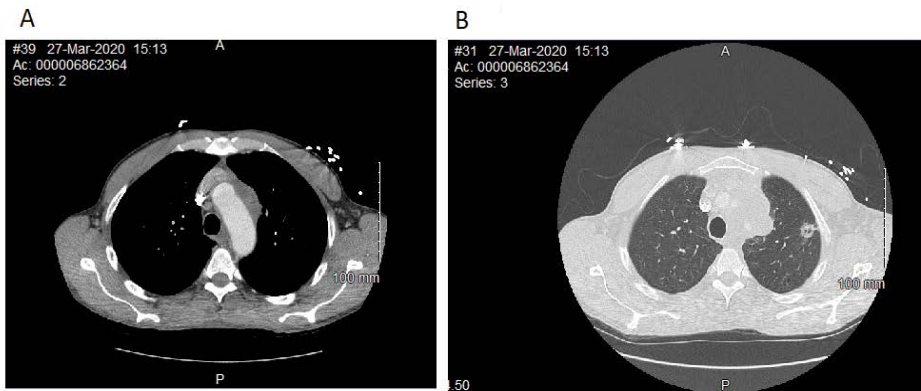


Figure 3: Chest computed tomography revealed left sided lobular mediastinal mass (a) and a spiculated cavitary nodule in left upper lobe (b).

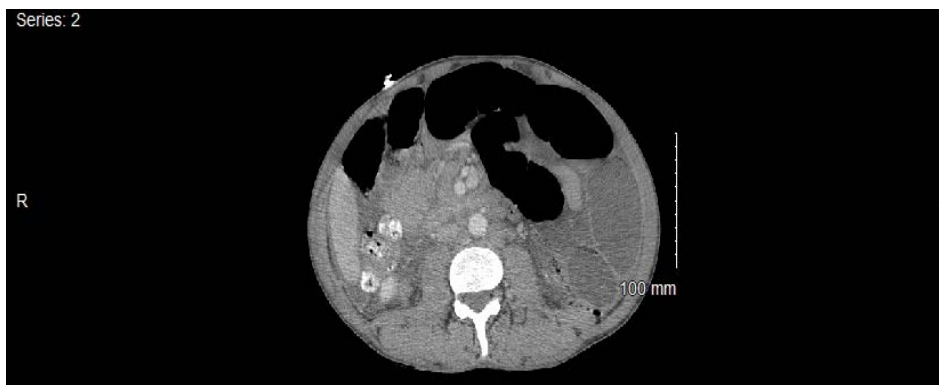

Figure 4: Abdominal CT scan revealed dilated small bowel consistent with small bowel obstruction.

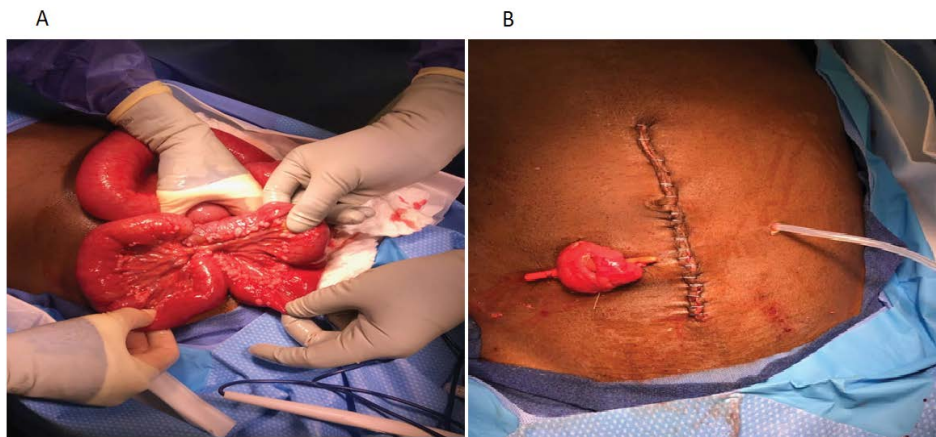


Figure 5: Diffuse carcinomatosis with seeding of the small bowel (a); diverting loop ileostomy completed and JP drain placed.

carcinomatosis. Immunohistochemical (IHC) staining showed that the tumor cells are positive for pancytokeratin AE1/AE3, focally positive for CK7 and weakly positive for TTF-1. Given the history of his lung cancer combined with surgical specimen analysis, we concluded that the intestinal obstruction was caused by peritoneal carcinomatosis due to advanced metastatic lung cancer.

Patient continued to follow up with an oncologist for palliative care. Patient is positive for MET amplification mutation, for which he was started on crizotinib as a targeted therapy. However, the patient was not able to absorb the medication effectively due to his ileostomy. Therefore, crizotinib was discontinued and intravenous chemotherapy was planned for his palliative care.

Discussion

The main risk factor for any lung cancer is smoking tobacco. There are various cancer-causing agents present in tobacco smoke; primary or secondary exposure increases the risk. Other risk factors include a family history of lung cancer or occupational exposure to other causative agents such as asbestos, radon, silica, heavy metals and diesel fumes. Genetic mutations in the p53 gene are the most frequent cause of tumorigenesis in NSCLC, accounting for 52% of cases [5]. Our patient had a past history of heavy smoking, drinking, and working in a high risk environment. The current recommendation for lung cancer screening is an annual low-dose CT scan in adults aged 55-80 years who currently smoke and have a 30 pack-year smoking history or quit within the last 15 years [6].

Adenocarcinoma of the lung is the most common primary lung cancer seen in the United States. It is part of the NSCLC and has a strong association with previous smoking [5]. While the incidence rate and mortality have declined, it remains the leading cause of cancer death in the United States. Adenocarcinoma of the lung usually evolves from the mucosal glands and represents about 40% of all lung cancers [5]. It is the most common subtype to be diagnosed in people who have never smoked. Lung adenocarcinoma

usually occurs in the lung periphery, and in many cases, may be found in scars or areas of chronic inflammation [5].

Approximately 40% of patients with lung cancer present with metastatic disease with the most common sites being to the bone, liver, brain, and adrenal glands [7]. Our patient presented with metastasis to the brain along with a rare case of peritoneal spread as well. Peritoneal carcinomatosis is most commonly seen in ovarian, colorectal, and gastric cancers. Primary tumors of the breast, melanoma, and lung cancer metastasizing to the peritoneum are a rare phenomenon. Out of autopsy results, peritoneal carcinomatosis from primary lung cancer was seen in 2.7%-16% [7]. It is speculated that certain characteristics such as its extensive surface area with presence and movement of fluid makes the peritoneum an ideal site for metastasis. Hematogenous spread is theorized to be the cause in patients with melanoma, lung, and breast cancers [8]. Metastasis to upper GI tract presents with bleeding whereas metastasis to the lower GI tract usually presents with intestinal obstruction with or without perforation [2]. Clinical manifestations of this complication may present as obstruction, perforation, ascites and are generally nonspecific. Therefore, peritoneal seeding should be considered in lung cancer patients with abdominal symptoms. Diagnosis is typically made by imaging techniques or biopsy [7]. In our case, it was discovered upon abdominal CT with definitive diagnosis made on exploratory laparotomy and biopsy.

Peritoneal carcinomatosis is often associated with a poor prognosis and minimally influenced by systemic chemotherapy with the median survival being no more than two months [9]. Treatment is done based on the presentation of the patient and the clinician must weigh the risk to reward ratio between palliative care and surgical intervention. Cytoreductive surgery is dependent on the characteristics of the spread which has been categorized into three types of patterns; Random Proximal, Complete, and Widespread distribution. Selective parietal peritonectomy is done for random proximal while a complete peritonectomy is indicated for complete and widespread with the goal to

reduce the tumor foci if possible [10]. Surgical Intervention paired with hyperthermic intraperitoneal chemotherapy (HIPEC) has shown promising results. A systematic review of 506 patients who underwent cytoreductive surgery with HIPEC for peritoneal carcinomatosis revealed a median survival rate of 19.2 months [11].

Our patient had a diverting loop ileostomy to relieve the symptoms of his SBO and was undergoing palliative care with a regimen of Crizotinib. Crizotinib is a first-generation small-molecule tyrosine kinase inhibitor which has been shown to be effective against lung cancers harboring *ROS1* alterations [12]. An objective response rate (ORR) of 72% and a median progression-free survival (PFS) of 19.2 months was reported in advanced *ROS1*-rearranged NSCLC based on a Phase I crizotinib trial. Therefore, accurate diagnoses are important with respect to the treatment and prognosis of NSCLC patients. Indeed, patients may survive longer after appropriate treatment.

Conclusion

The patient presented with lung cancer, metastasized to the GI tract, peritoneum, and brain. The peritoneal pelvic mass illustrates the distinct nature of the case. Peritoneal carcinomatosis is more commonly associated with cancer of the ovary, colon, and GI tract, rather than cancer of the lung. The metastasis of cancer as rendered the 52-year-old patient cachectic and in palliative care. The greatest risk factor for developing lung cancer is smoking tobacco; however, his occupation as a mechanic posed an additional risk factor. The case-report presents an opportunity for implementing advanced screening techniques for lung cancer. In particular, regular screenings are recommended for patients who smoke tobacco with low-dose CT. Clinicians should consider the detriment undiagnosed lung cancer may have on their patients and rare etiologies for SBO.

Acknowledgements

We thank Dr. Kaizan Kalyaniwalla, Department of Radiology, and Dr. Isoken Koko, Department of Oncology for their contributions and suggestions in this case report.

Conflict of Interest Statement

The authors declare that they have no competing interests.

Funding

Not applicable.

Notes

Consent for Publication

We obtained written informed consent from the patient for publication of this case report and accompanying images. The Editor-in-Chief of this journal has a copy of the written consent available for review.

References

- Hu Y, Feit N, Huang Y, Xu W, Zheng S, Li X. Gastrointestinal metastasis of primary lung cancer: An analysis of 366 cases. *Oncol Lett.* 2018;15(6):9766-9776. doi: 10.3892/ol.2018.8575.
- Misiakos EP, Gouloumi AR, Schizas D, Damaskou V, Tsapralis D, Farrugia FA, et al. Small bowel perforation with multiple intestinal metastases from lung carcinoma: A case report. *Oncol Lett.* 2019;17(4):3862-3866. doi: 10.3892/ol.2019.10031.
- Yoshimoto A, Kasahara K, Kawashima A. Gastrointestinal metastases from primary lung cancer. *European Journal of Cancer.* 2006;42(18):3157-3160.
- Janez J. Acute intestinal obstruction due to metastatic lung cancer-case report. *J Surg Case Rep.* 2017;2017(2):rjx031. doi: 10.1093/jscr/rjx031.
- Myers DJ, Wallen JM. Cancer, Lung Adenocarcinoma. [Updated 2019 Jan 11]. In: StatPearls [Internet]. Treasure Island (FL): StatPearls Publishing; 2020 Jan. Available from: <https://www.ncbi.nlm.nih.gov/books/NBK519578/>
- Tanoue LT, Tanner NT, Gould MK, Silvestri GA. Lung cancer screening. *Am J Respir Crit Care Med.* 2015;191(1):19-33. doi:10.1164/rccm.201410-1777CI.
- Sereno M, Rodríguez-Esteban I, Gómez-Raposo C, Merino M, López-Gómez M, Zambrana F, et al. Lung cancer and peritoneal carcinomatosis. *Oncol Lett.* 2013;6(3):705-708. doi: 10.3892/ol.2013.1468.
- Mikuła-Pietrasik J, Uruski P, Tykarski A, Książek K. The peritoneal "soil" for a cancerous "seed": a comprehensive review of the pathogenesis of intraperitoneal cancer metastases. *Cell Mol Life Sci.* 2018;75(3):509-525. doi: 10.1007/s00018-017-2663-1.
- Hanane K, Salma B, Khadija B, Ibrahim E, Saber B, Hind M, et al. Peritoneal carcinomatosis, an unusual and only site of metastasis from lung adenocarcinoma. *Pan Afr Med J.* 2016;23:60. doi: 10.11604/pamj.2016.23.60.8910.
- Coccolini F, Gheza F, Lotti M, Virzi S, Iusco D, Ghermandi C, et al. Peritoneal carcinomatosis. *World J Gastroenterol.* 2013;19(41):6979-94. doi: 10.3748/wjg.v19.i41.6979.
- Glehen O, Kwiatkowski F, Sugarbaker PH, Elias D, Levine EA, De Simone M, et al. Cytoreductive surgery combined with perioperative intraperitoneal chemotherapy for the management of peritoneal carcinomatosis from colorectal cancer: a multi-institutional study. *J Clin Oncol.* 2004;22(16):3284-92. doi: 10.1200/JCO.2004.10.012.
- Chen HF, Zhang QX, Zhu YC, Du KQ, Li XF, Wu LX, et al. Intestinal metastasis from primary *ROS1*-positive lung adenocarcinoma cancer patients responding to crizotinib. *Onco Targets Ther.* 2018;11:7821-7825. doi: 10.2147/OTT.S178985.

***Corresponding author:** Molly S. Jain, MS3, Saint James School of Medicine, 3321 Conservation Drive, Windsor ON N8W 5P2, CANADA, Tel:810-986-3063; E-mail: mjain@mail.sjmsm.org

Received Date: August 19, 2020, **Accepted Date:** September 11, 2020, **Published Date:** September 18, 2020.

Copyright: © 2020 Jain MS, et al. This is an open access article distributed under the Creative Commons Attribution License, which permits unrestricted use, distribution, and reproduction in any medium, provided the original work is properly cited.

Citation: Jain MS, Luvsannyam E, Kallan AR, Azizz N, Hasnie A, et al. (2020) A Rare Case of Peritoneal Carcinomatosis Leading to Bowel Obstruction Due to Metastatic Lung Cancer. *J Clin Tri Cas Rep* 3(1): 102.